

Conjunctival Prolapse under scleral contact lens

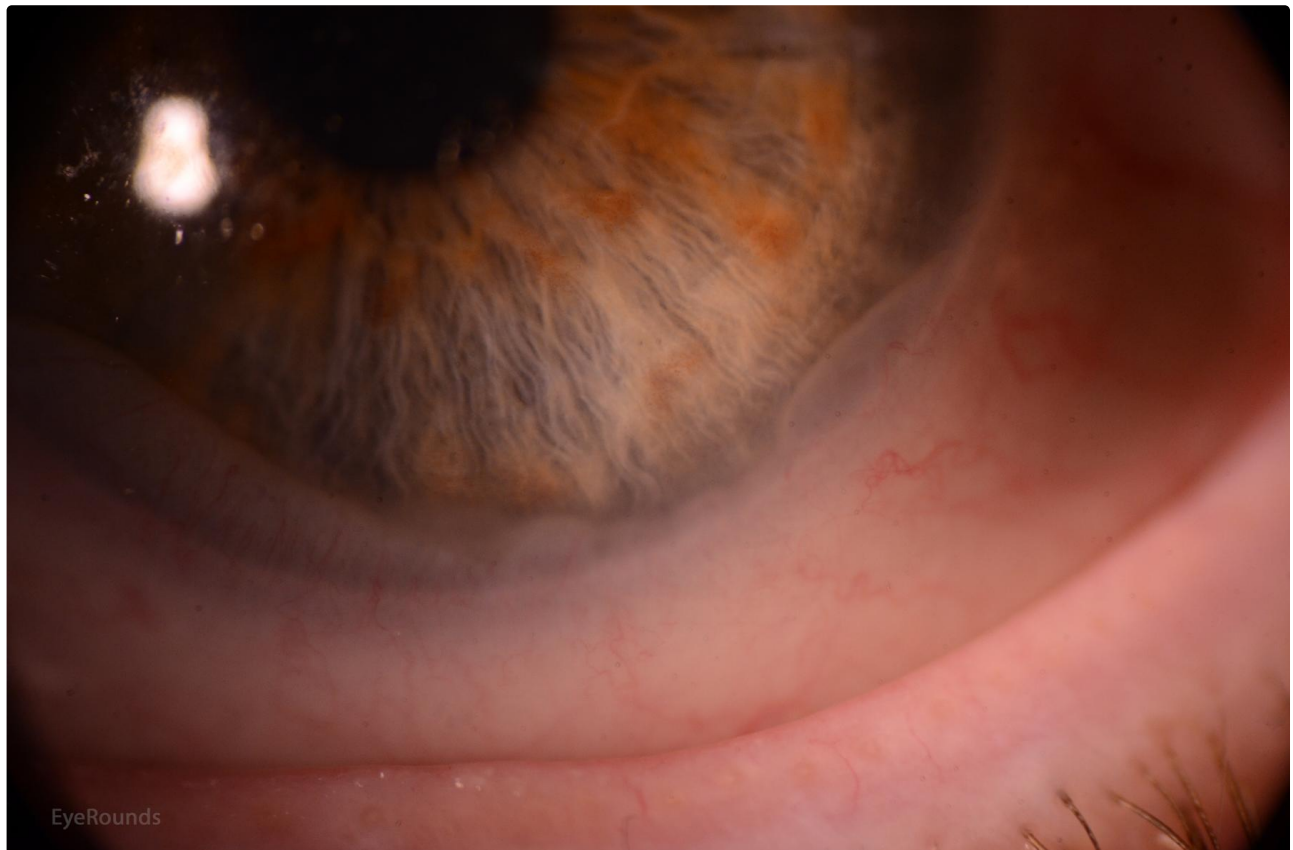Category(ies): [Contact Lens](#)

Contributor: [Tressa Larson OD FAAO](#)

Photographer: [Tressa Larson OD FAAO](#)



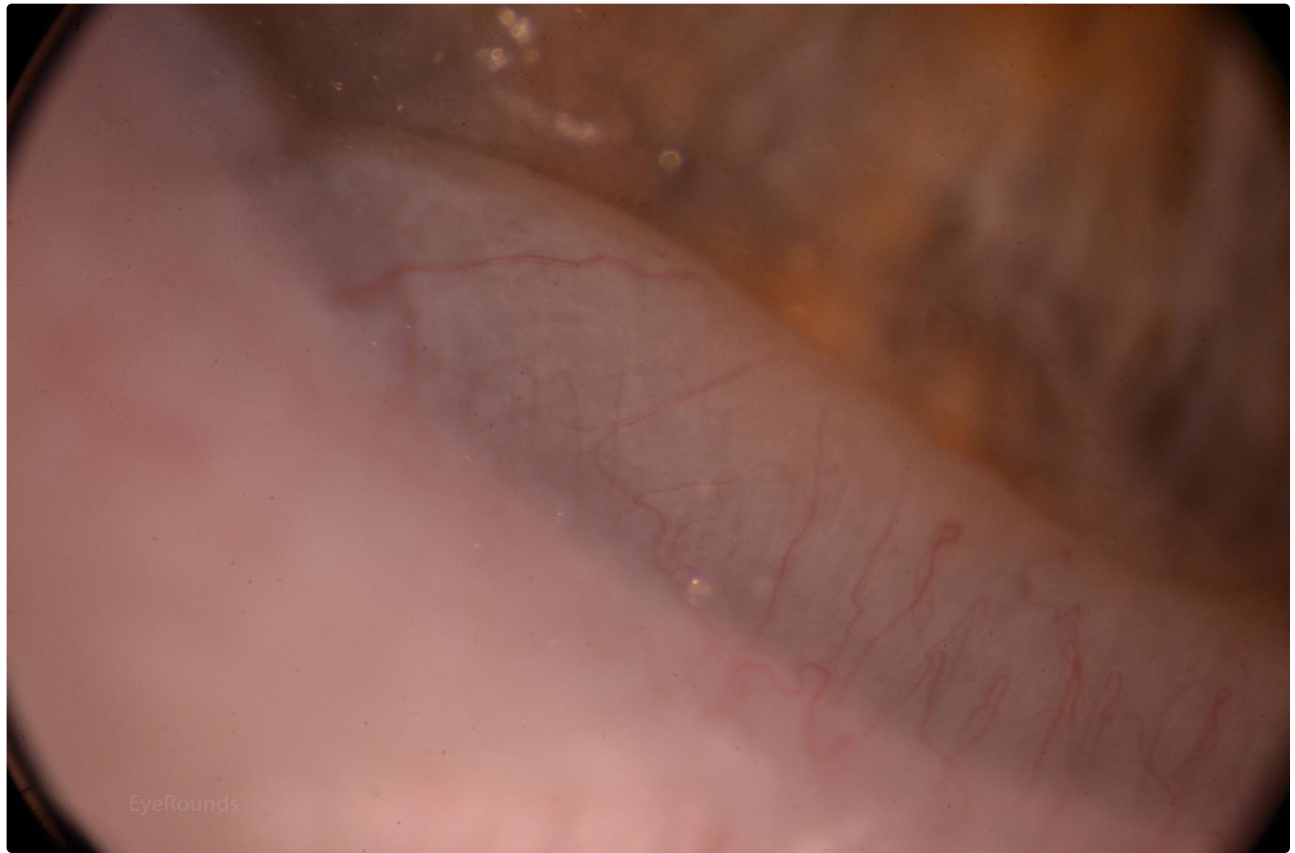
In some scleral contact lens wearers, the conjunctiva is sucked up into the bowl of the scleral contact lens resulting in wavy white folds at the peripheral cornea. While disturbing in appearance, there is no pathology associated with this and the fit does not need to be adjusted to eliminate it.



EyeRounds

[Enlarge](#)

[Download](#)



[Enlarge](#)

[Download](#)

Image Permissions:



Ophthalmic Atlas Images by EyeRounds.org, The University of Iowa are licensed under a [Creative Commons Attribution-NonCommercial-NoDerivs 3.0 Unported License](https://creativecommons.org/licenses/by-nc-nd/3.0/).

Address

University of Iowa
Roy J. and Lucille A. Carver College
of Medicine
Department of Ophthalmology and
Visual Sciences
200 Hawkins Drive
Iowa City, IA 52242

Legal

Copyright © 2019 The University of
Iowa. All Rights Reserved
[Report an issue with this page](#)
[Web Privacy Policy](#) |
[Nondiscrimination Statement](#)

Related Links

[Cataract Surgery for Greenhorns](#)
[EyeTransillumination](#)
[Gonioscopy.org](#)
[Iowa Glaucoma Curriculum](#)
[Iowa Wet Lab](#)
[Patient Information](#)
[Stone Rounds](#)

EyeRounds Social Media

Follow



Receive notification of new cases,
[sign up here](#)
[Contact Us](#)

